

7. Guilbert TW, MD, Mauger DT, Allen DB, et al. Growth of preschool children at high risk for asthma 2 years after discontinuation of fluticasone. *J Allergy Clin Immunol.* 2011;128:956-63.
8. Bacharier LB, Phillips BR, Zeiger RS, Szefer SJ, Martinez FD, Lemanske RF, et al. Episodic use of an inhaled corticosteroid or leukotriene receptor antagonist in preschool children with moderate-to-severe intermittent wheezing. *J Allergy Clin Immunol.* 2008;122:1127-35.
9. Guilbert TW, Morgan WJ, Zeiger RS, Mauger DT, Bohemer SJ, Szefer SJ, et al. Long-term inhaled corticosteroids in preschool children at high risk for asthma. *N Engl J Med.* 2006;354:1985-97.
10. Jartti T, Lehtinen P, Vanto T, et al. Evaluation of the efficacy of prednisolone in early wheezing induced by rhinovirus or respiratory syncytial virus. *Pediatr Infect Dis J.* 2006;25:482-8.
11. Lemanske RF Jr, Jackson DJ, Gangnon RE, Evans MD, Li Z, Shult PA, et al. Rhinovirus illnesses during infancy predict subsequent childhood wheezing. *J Allergy Clin Immunol.* 2005;116:571-7.
12. Lehtinen P, Ruohola A, Vanto T, Vuorinen T, Ruuskanen O, Jartti T. Prednisolone reduces recurrent wheezing after a first wheezing episode associated with rhinovirus infection or eczema. *J Allergy Clin Immunol.* 2007;119:570-5.
13. Jartti T, Lee WM, Pappas T, Evans M, Lemanske RF Jr, Gern JE. Serial viral infections in infants with recurrent respiratory illnesses. *Eur Respir J.* 2008;32:314-20.
14. Panickar J, Lakhanpaul M, Lambert PC, Kenia P, Stephenson T, Smyth A, et al. Oral prednisolone for preschool children with acute virus-induced wheezing. *N Engl J Med.* 2009;360:329-38.
15. Jartti T, Kuusipalo H, Vuorinen T, et al. Allergic sensitization is associated with rhinovirus-, but not other virus-, induced wheezing in children. *Pediatr Allergy Immunol.* 2010;21:1008-14.
16. Jartti T, Korppi M. Rhinovirus-induced bronchiolitis and asthma development. *Pediatr Allergy Immunol.* 2011;22:350-5.

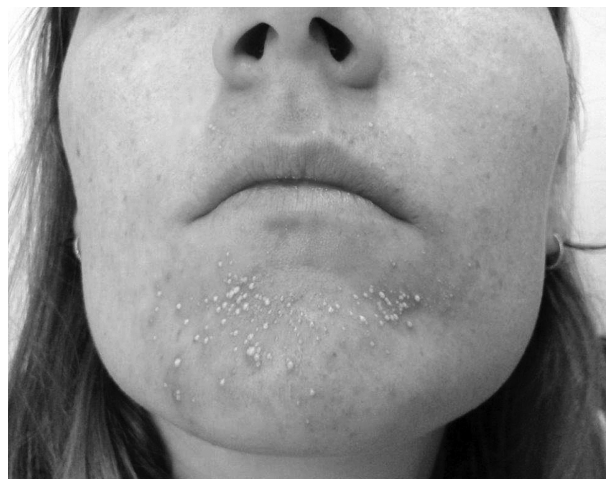
### Acute localized exanthematous pustulosis (ALEP) caused by the association amoxicillin-clavulanic acid

*Braz J Allergy Immunol.* 2013;1(3):182-3.

Acute localized exanthematous pustulosis (ALEP) is an atypical variant of the rare drug reaction acute generalized exanthematous pustulosis (AGEP).<sup>1</sup> It is an acute and localized aseptic subcorneal pustular eruption caused by medicines.<sup>2</sup> It is usually present 24 hours after exposure and in about 80% of the reported cases it is caused by antibiotics, especially beta-lactam agents.<sup>3</sup> The diagnosis is clinical (cause-effect, temporal association) and the condition is reversible in about 2 weeks after discontinuation of the responsible drug and treatment with systemic corticosteroid.<sup>4-5</sup> A few cases of ALEP attributed to the oral combination amoxicillin-clavulanic acid have been described.<sup>6-7</sup>

Female patient, age 26 years, Caucasian, lawyer, treated with the oral combination of amoxicillin (875 mg)-clavulanic acid (125 mg), every 12 hours, for an inguino-crural infection. After 24 hours of this treatment, she presented with dizziness and a painful and pruritic

pustular eruption on her chin (Figure 1). A similar eruption was triggered by the same antibiotic combination 3 years ago after surgery for acute appendicitis. She also has irritable bowel syndrome and vasovagal reactions for many months. She has been on oral contraceptives for many years. She presented a positive family history for asthma and rhinitis. Physical examination was otherwise normal with an axillary's temperature of 36.4°C. She was diagnosed as having recurrent ALEP caused by the combination of amoxicillin-clavulanic acid, which was immediately discontinued. Oral fexofenadine 180mg/day and prednisone 20mg /twice a day were instituted with complete resolution of the pustulous eruption in 3 days. The following laboratory work-up was normal or negative: CBC, differential, platelets, ESR, CRP, aspartate aminotransferase and alanine aminotransferase (AST and ALT), serum immunoglobulins (IgG, IgA, IgM, IgE), complement (C3, C4 and CH50), anti-HIV-1&2, and lymphocyte subpopulations (CD3+, CD19+, CD4+, CD8+, CD4+/CD8+ ratio, CD56+, CD16+). Gamma GT was elevated (67 U/L with a normal value lower than 40 U/L), and a positive ANA of 1:320 with a nuclear fine dense pattern was detected but it was negative for all the other pertinent cell structures. These were considered as non specific laboratory changes.



**Figure 1 -** Acute localized exanthematous pustulosis (ALEP) on the chin caused by the combination amoxicillin-clavulanic acid

**Mario Geller, MD, MACP, FAAAAI, FAAAAI**

Active Member of the Academy of Medicine of Rio de Janeiro, Brazil  
Geller Allergy and Immunology Clinic  
E-mail: gellerm@attglobal.net

No conflicts of interest.

## REFERENCES

---

1. Vickers JL, Matherne RJ, Mainous EG, Kelly BC. Acute localized exanthematous pustulosis: a cutaneous drug reaction in a dental setting. *J Am Dent Assoc.* 2008;139(9):1200-3.
2. Prange B, Marini A, Kalke A, Hodzic-Avdagic N, Ruzicka T, Hengge UR. Acute localized exanthematous pustulosis (ALEP). *J Dtsch Dermatol Ges.* 2005;3(3):210-2.
3. Roujeau JC, Bioulac-Sage P, Bourseau C, Guillaume JC, Bernard P, Lok C, Plantin P, Claudy A, Delavierre C, Vaillant L, et al. Acute generalized exanthematous pustulosis. Analysis of 63 cases. *Arch Dermatol.* 1991;127(9):1333-8.
4. Belda Junior W, Ferolla AC. Acute generalized exanthematous pustulosis (AGEP). Case report. *Rev Inst Med Trop Sao Paulo.* 2005;47(3):171-6.
5. Sim HS, Seol JE, Chun JS, Seo JK, Lee D, Sung HS. Acute localized exanthematous pustulosis on the face. *Ann Dermatol.* 2011;23(Suppl 3):S368-70.
6. Betto P, Germi L, Bonoldi E, Bertazzoni M. *Int J Dermatol.* 2008;47(3):295-6.
7. Ozkaya-Parlakay A, Azkur D, Kara A, Yildiz Y, Orhan D, Cengiz AB, Ersoy-Evans S. Localized acute generalized exanthematous pustulosis with amoxicillin and clavulanic acid. *Turk J Pediatr.* 2011;53(2):229-32.